

# 2014 Arlington Hospital Center Medical Brigade to San Benito Hospital in Cumayagua, Honduras



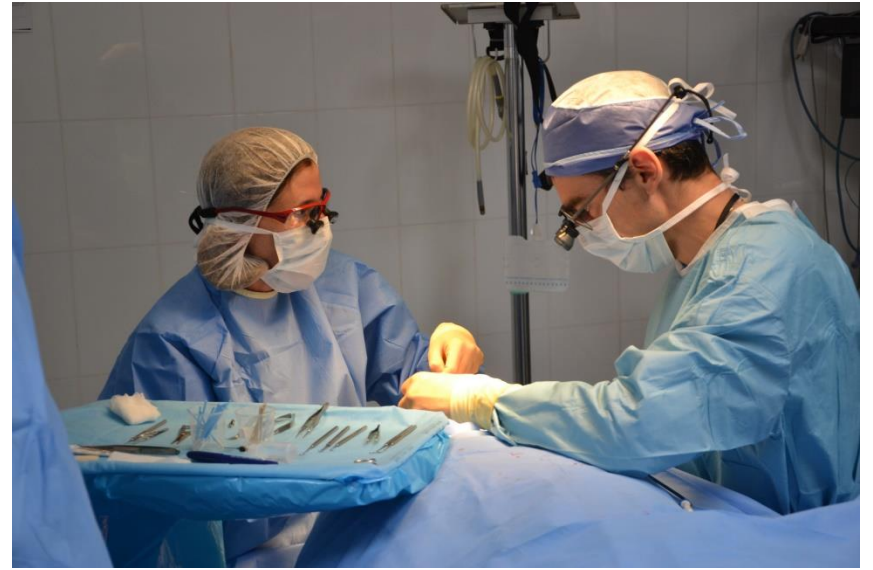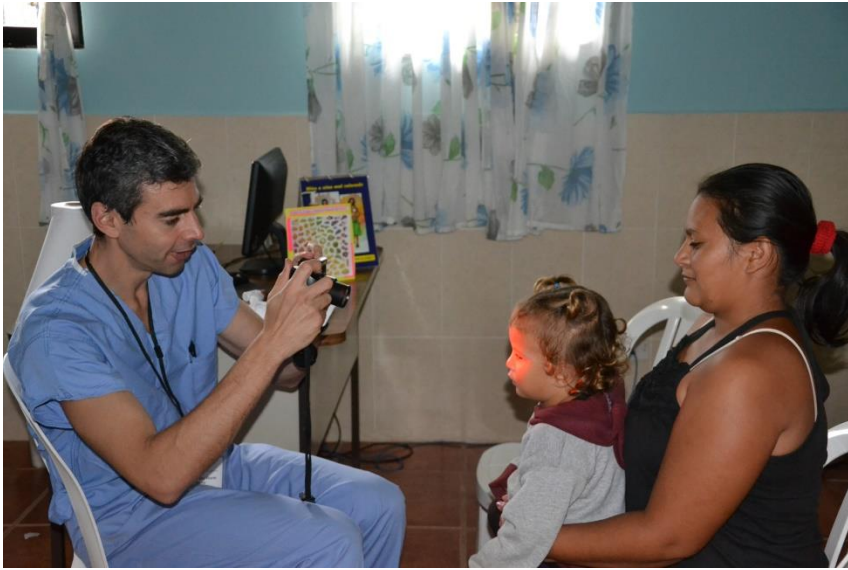# Daily commute





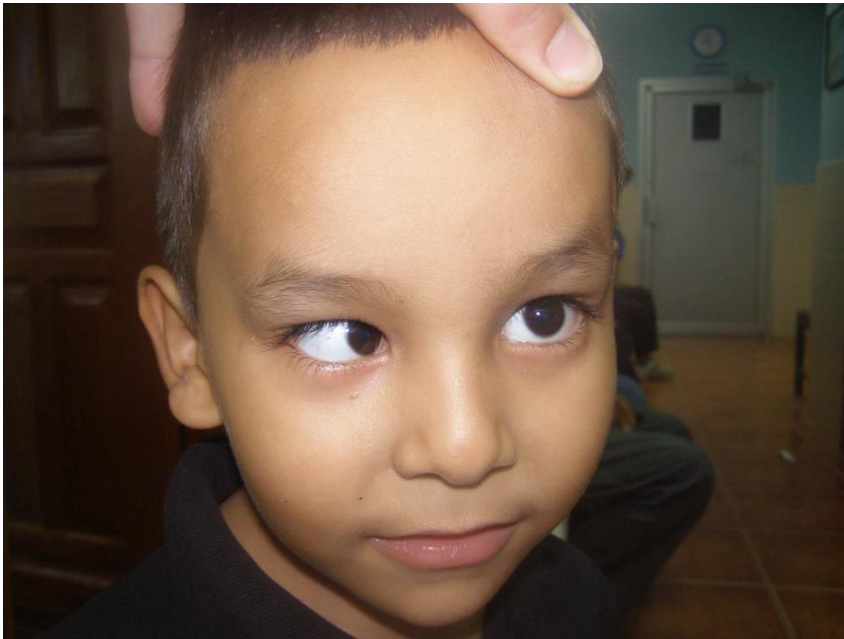




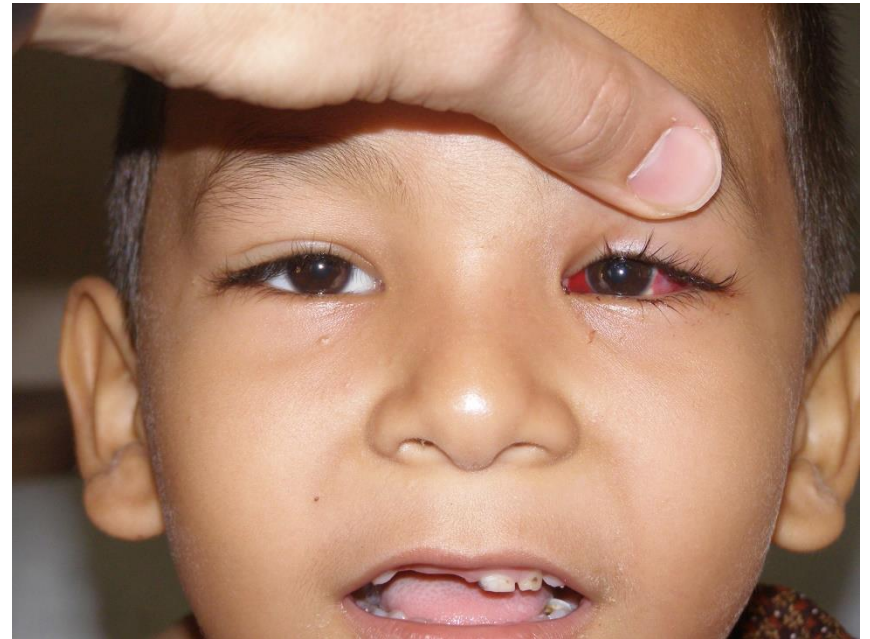
# Duanes's esotropia left eye

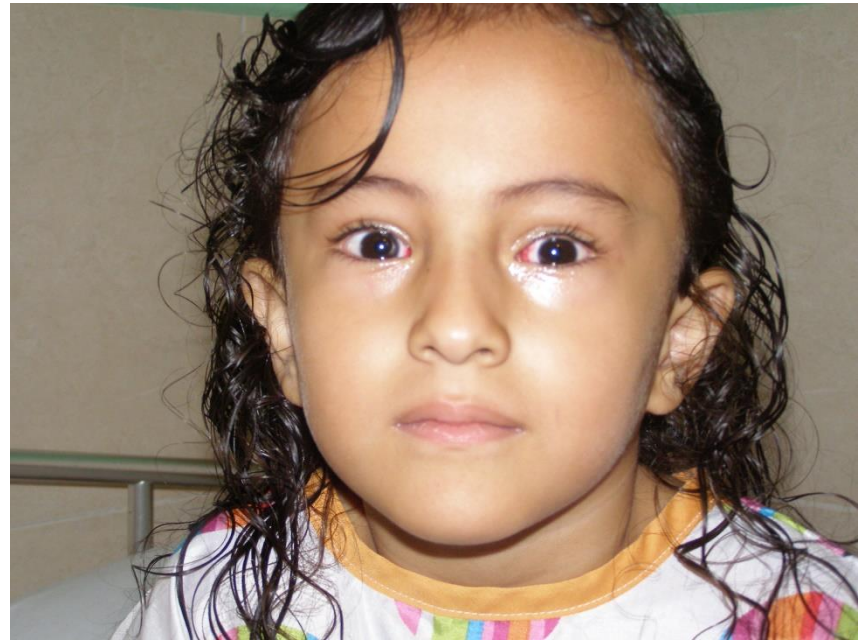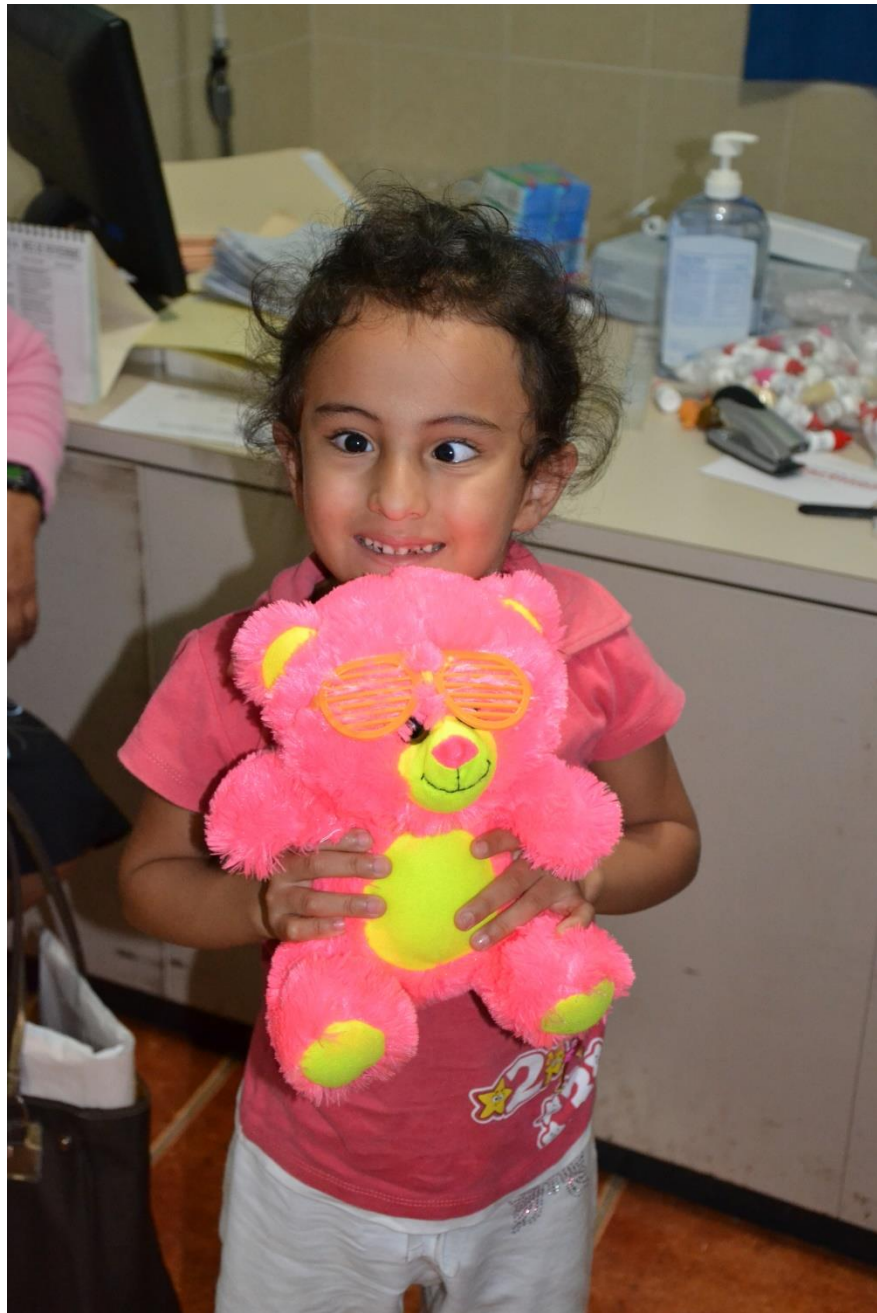Before



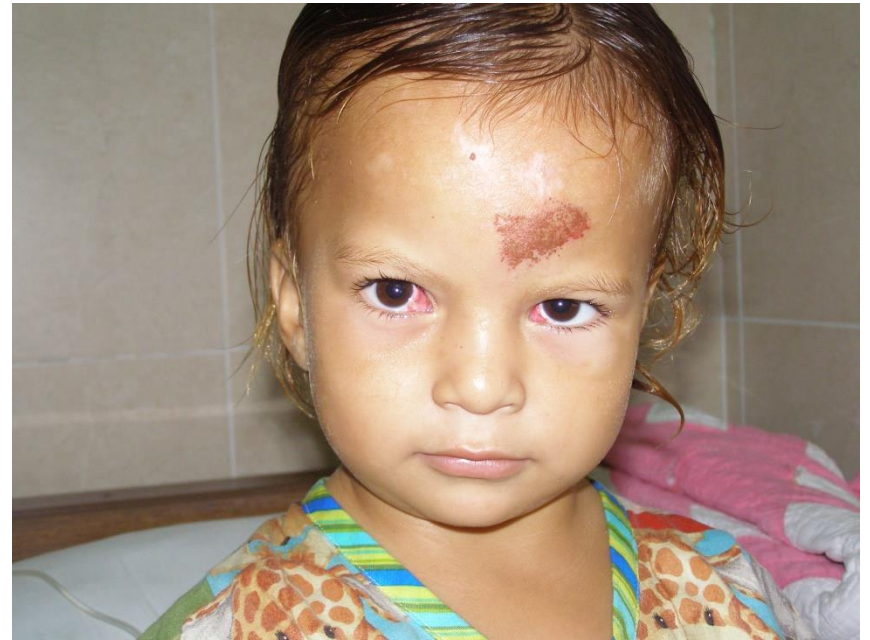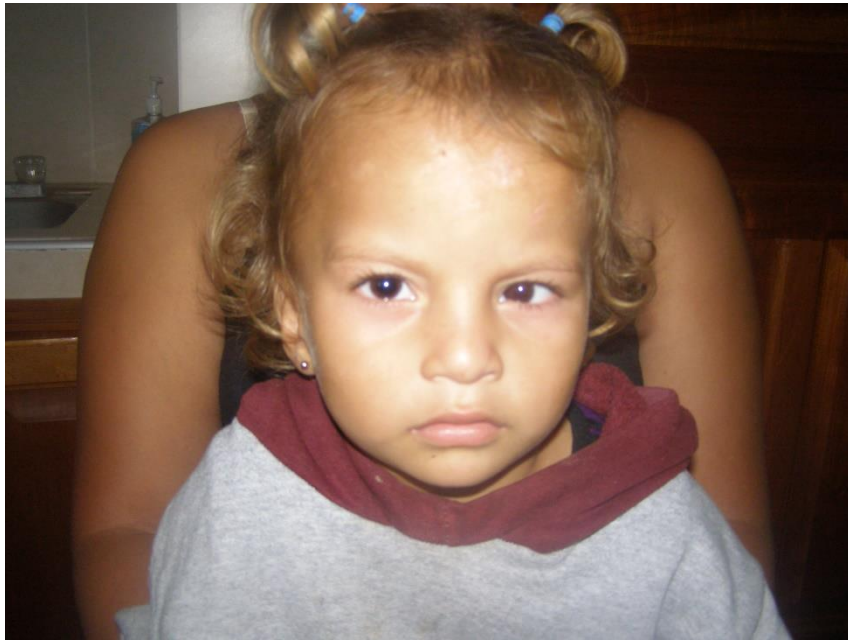1 day after surgery

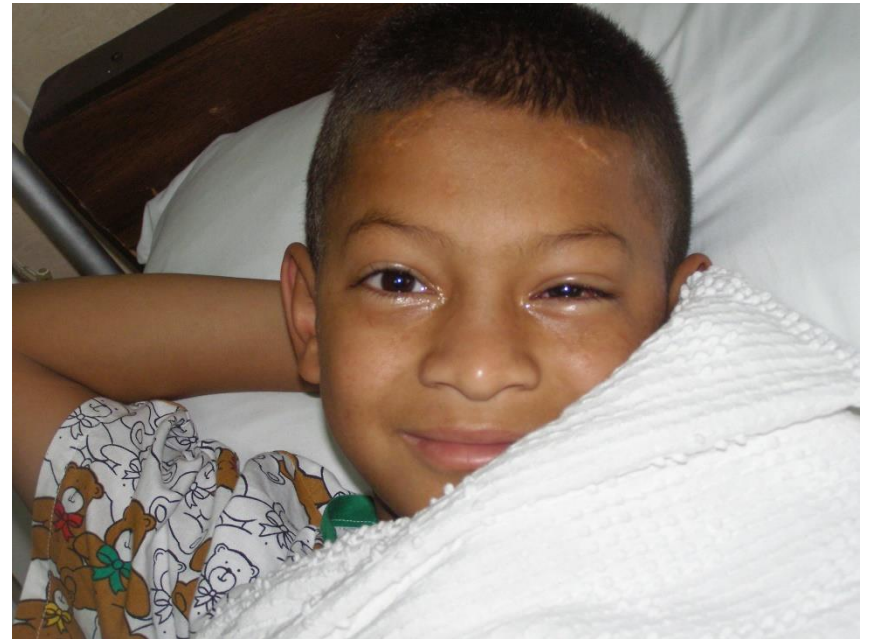


(redness and puffy lids does get back after a few days)



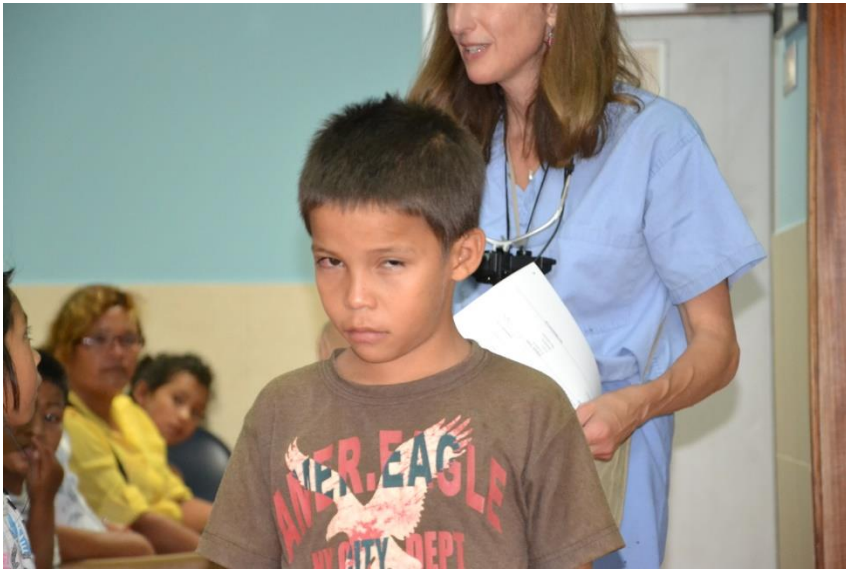



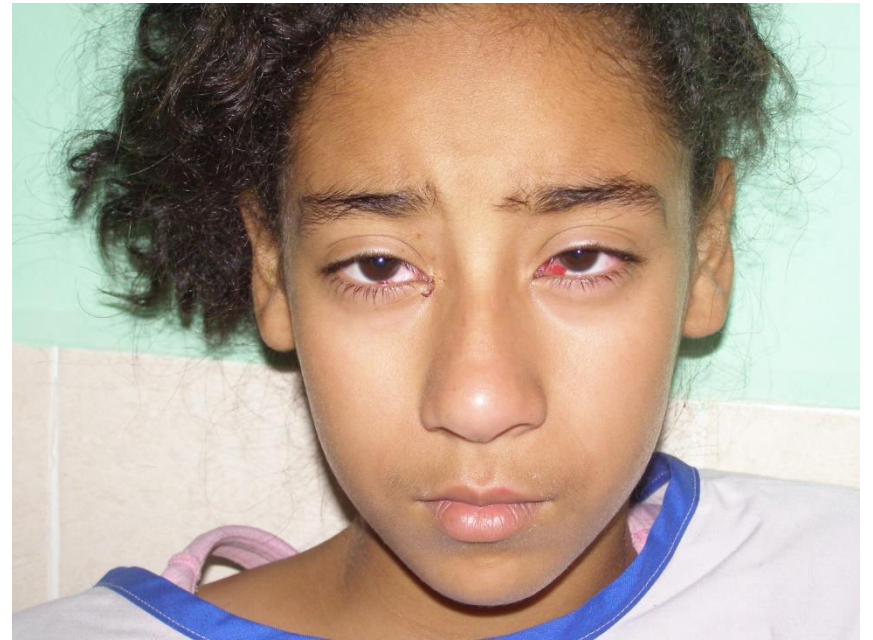
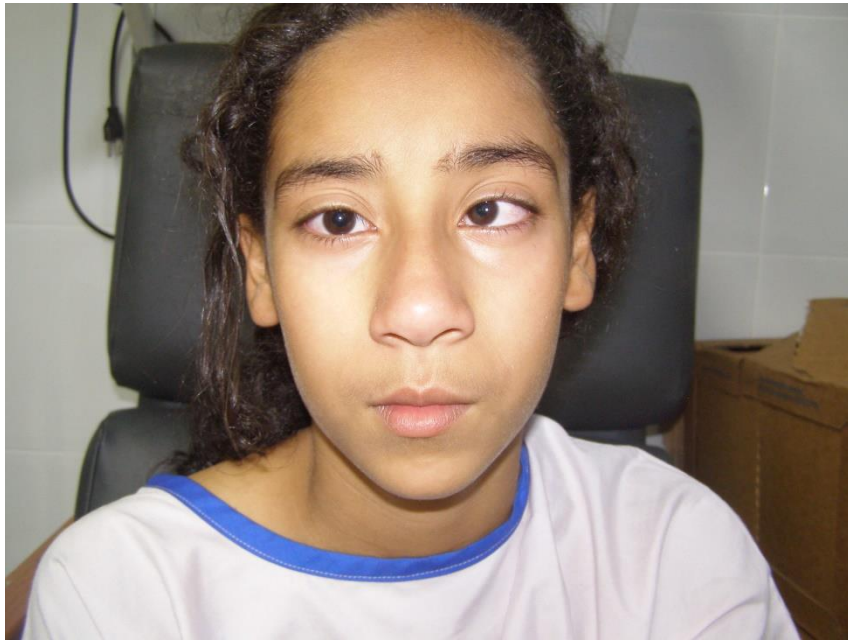




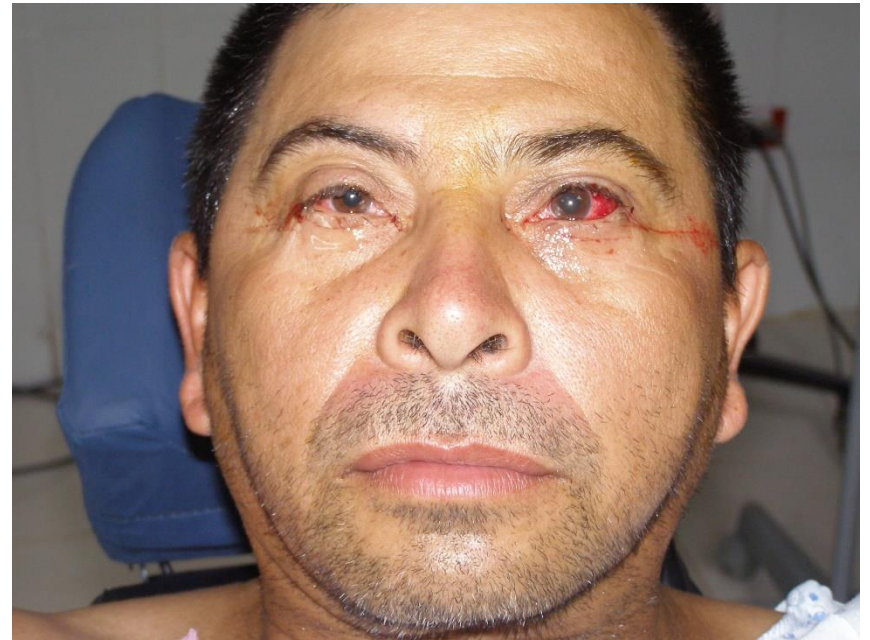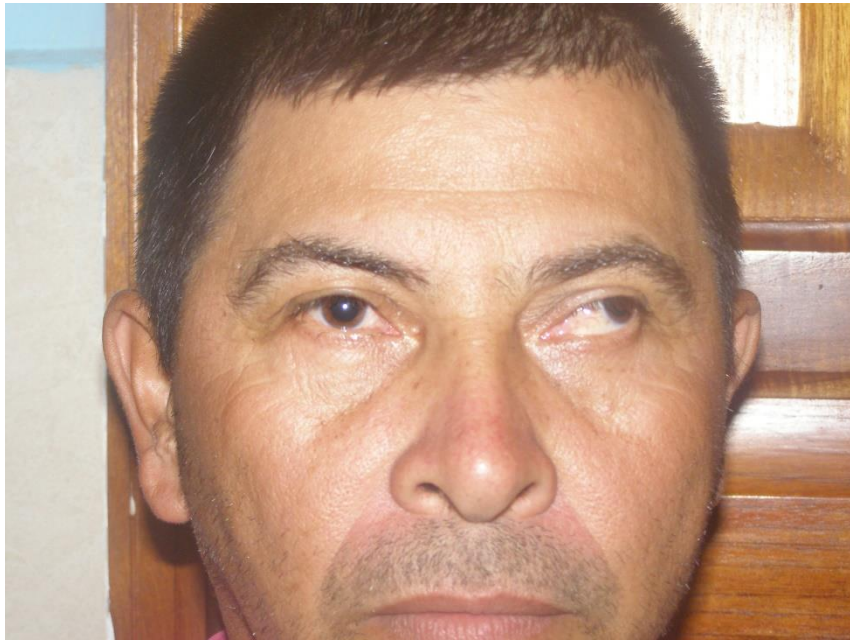
# Kestenbaum procedure for patient with Nystagmus with head turn

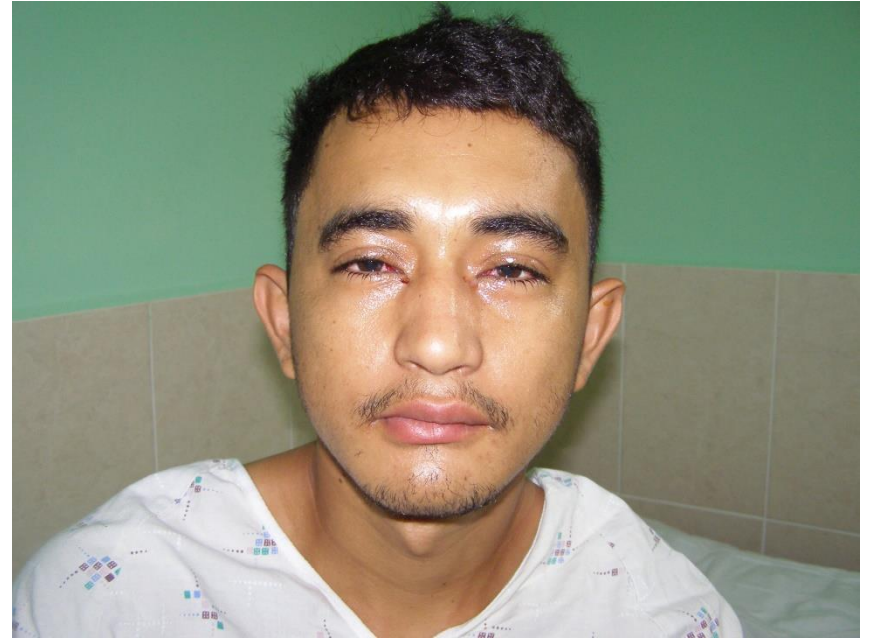
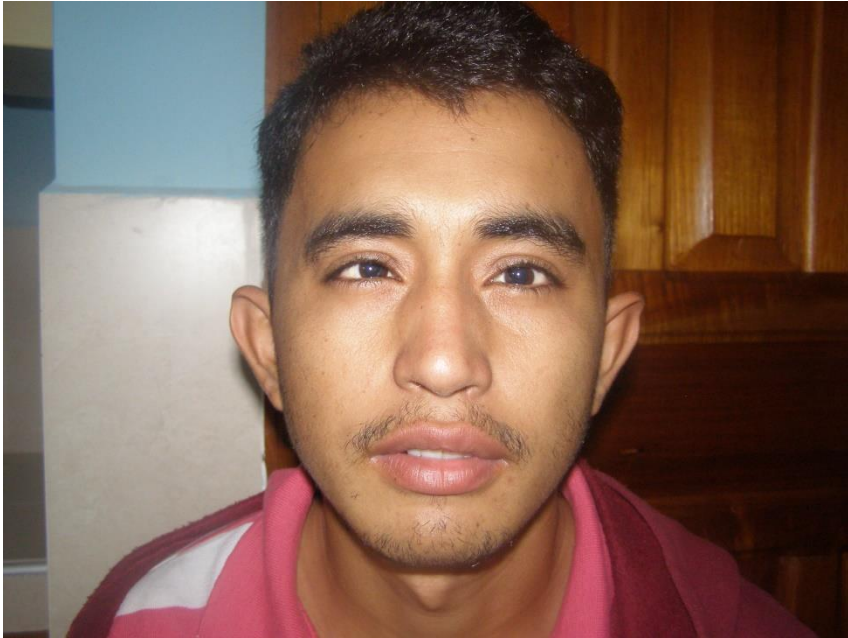
Dad traveled over 6hrs to bring son last year, had to postpone surgery until this year because kiddo got sick



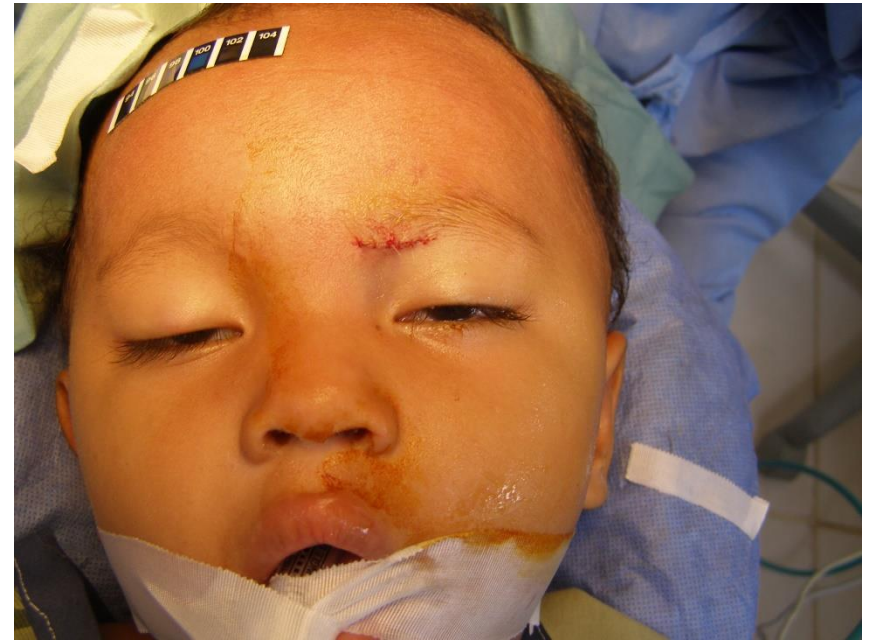
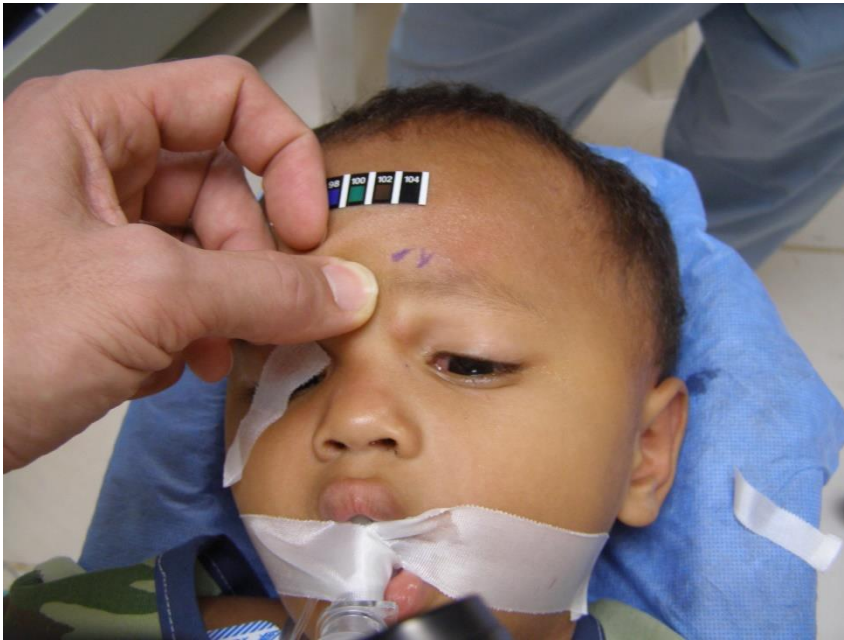






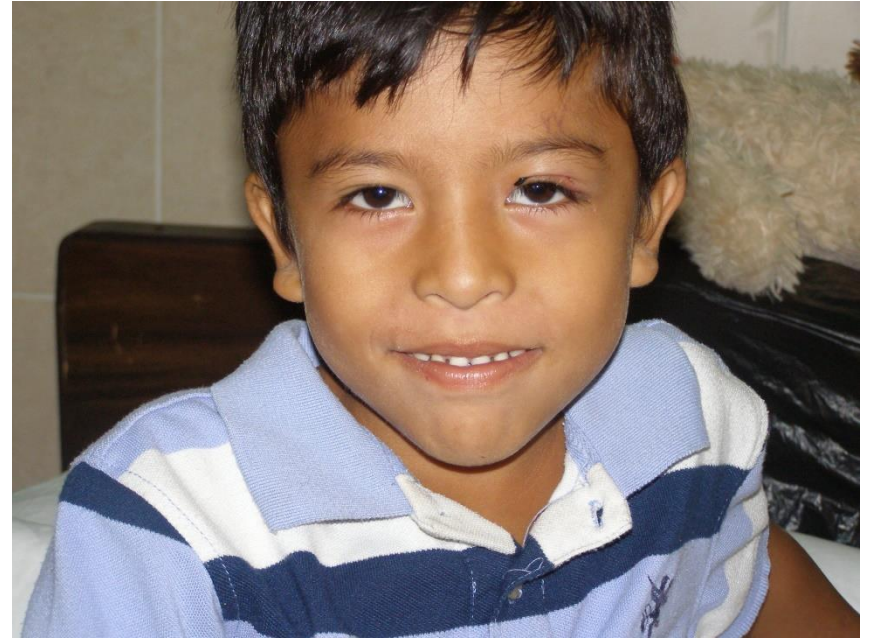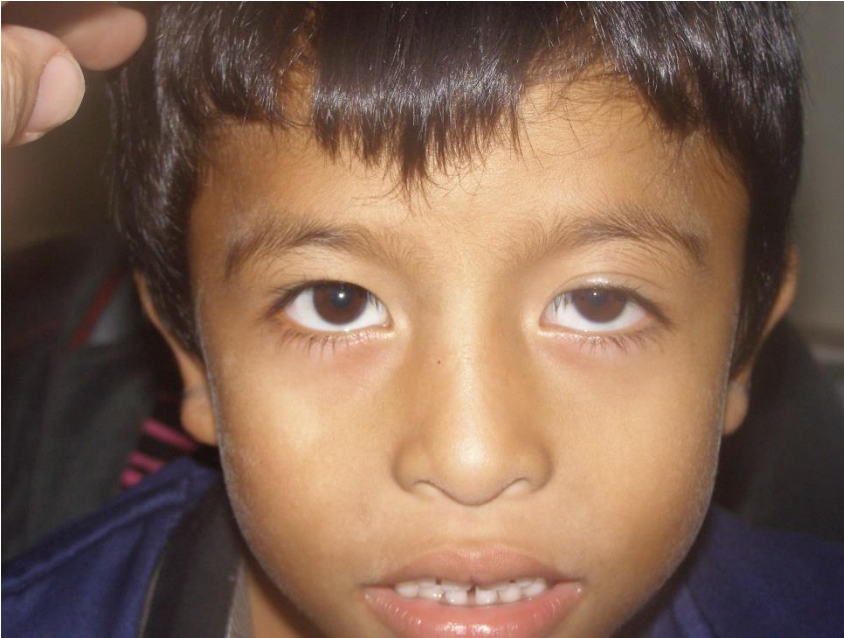# Superior nasal dermoid benign tumor



# Ptosis left upper lid

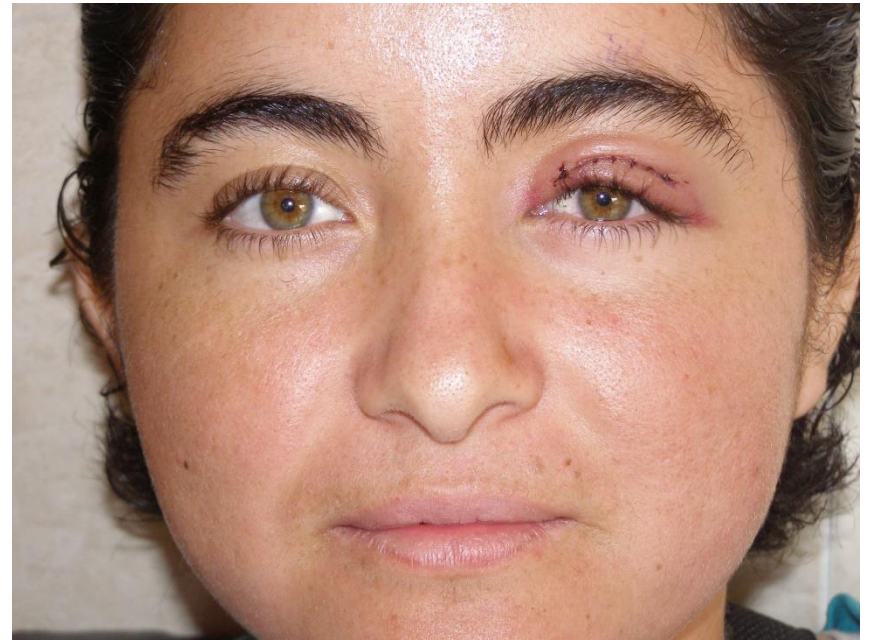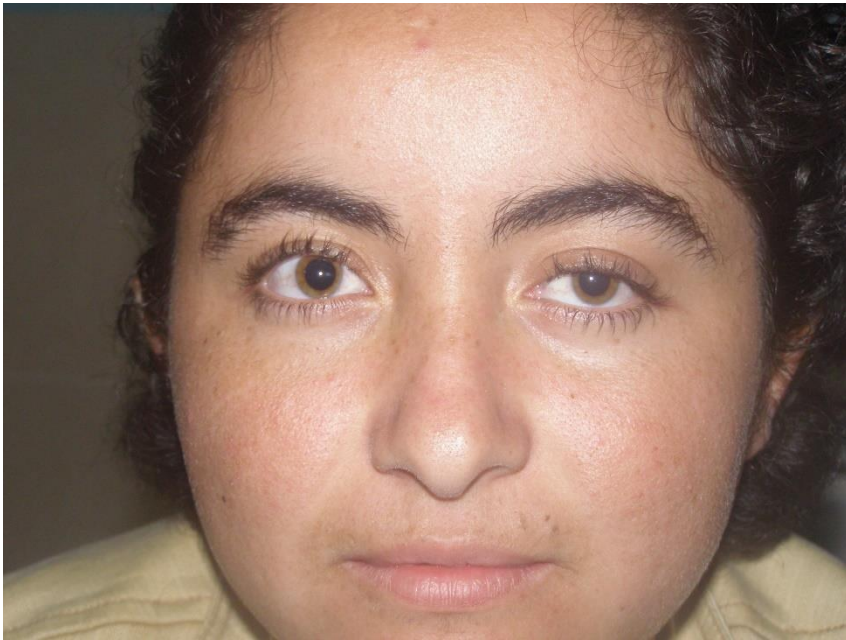
## Levator resection surgery



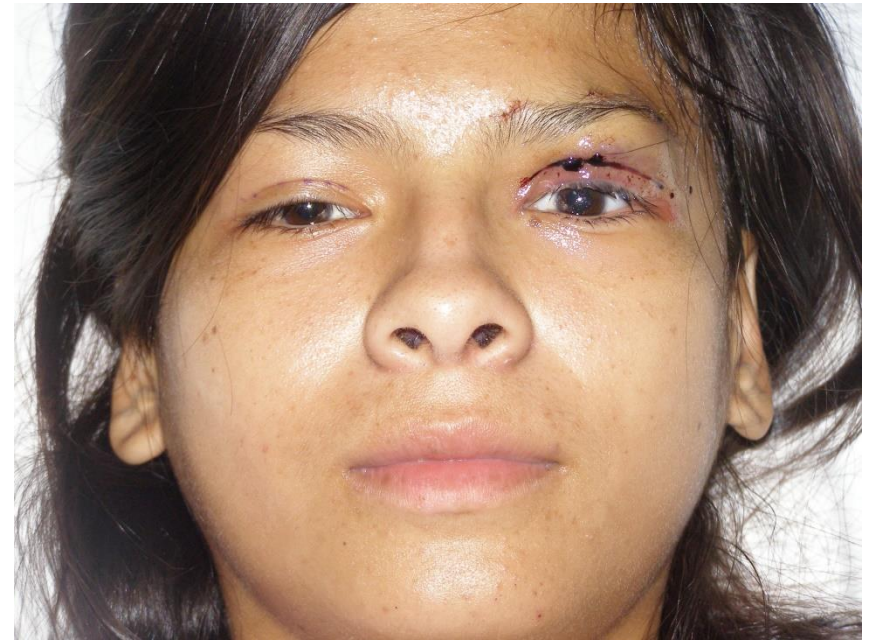
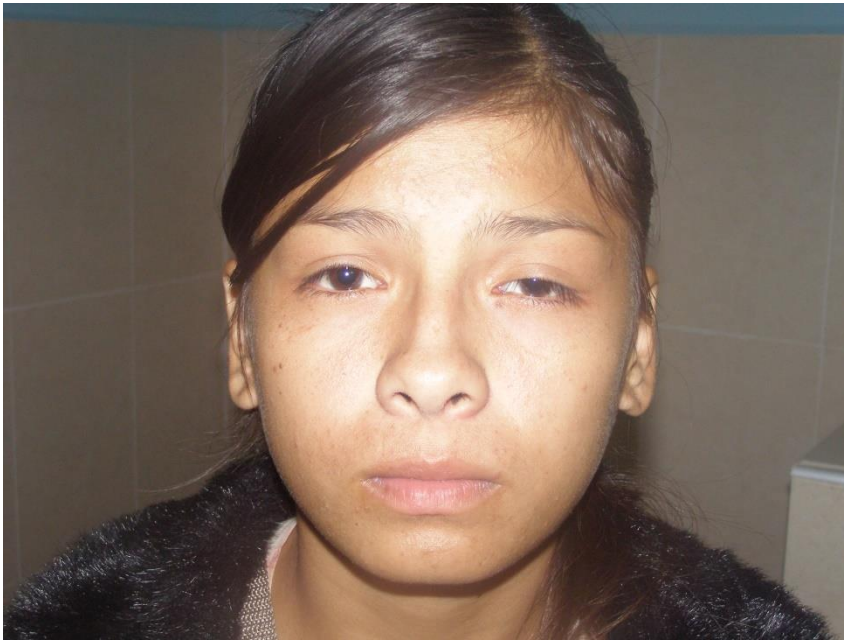
# Ptosis left upper lid

## Levator resection surgery

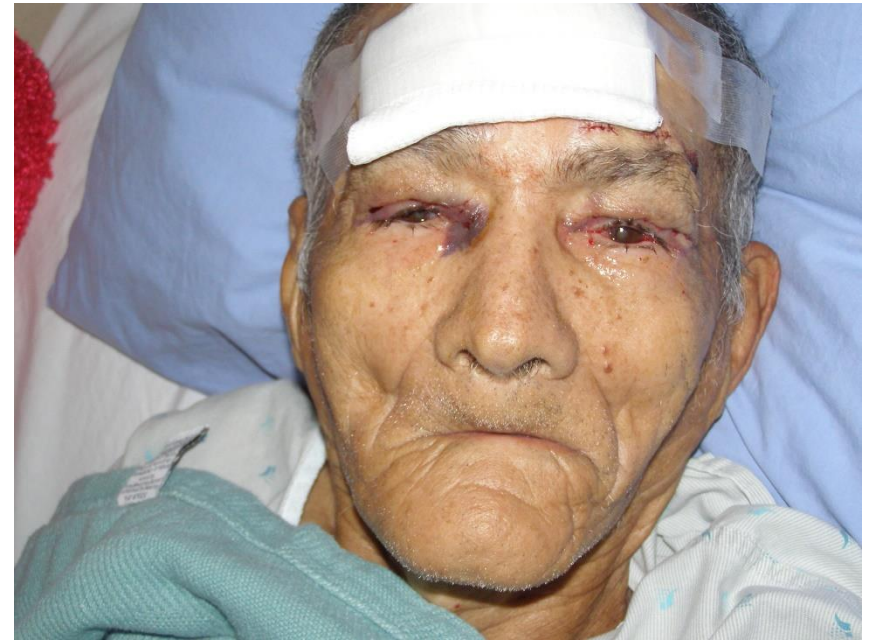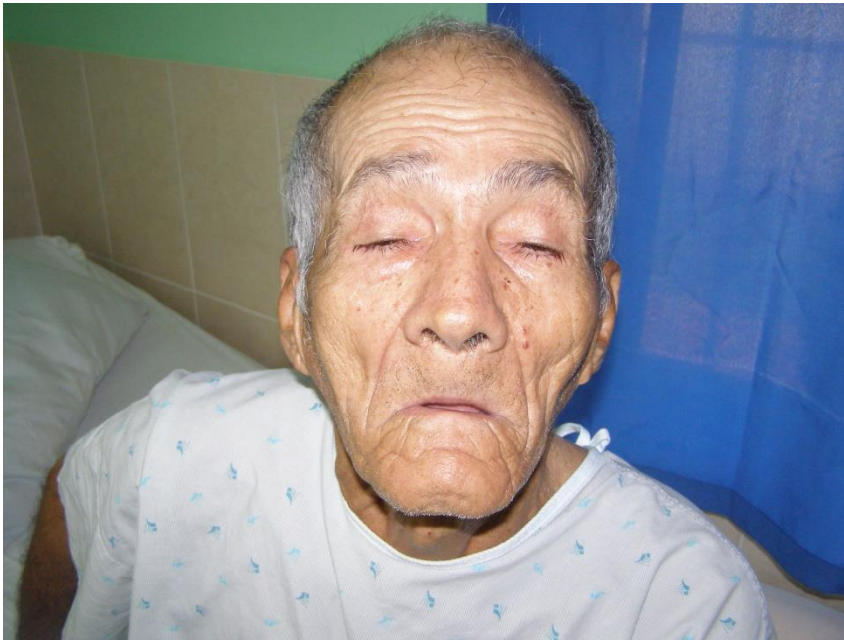


# Ptosis left upper lid Frontalis Sling surgery

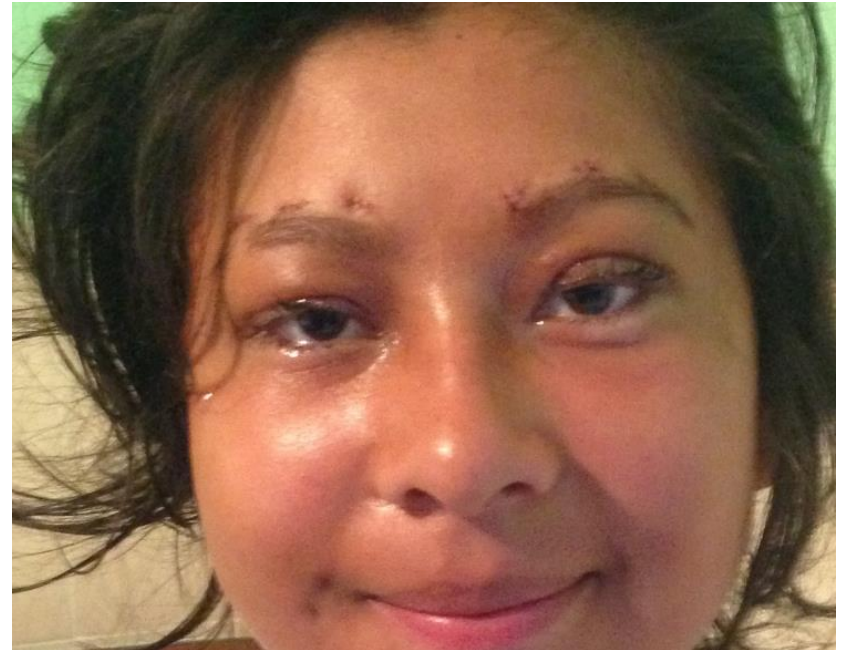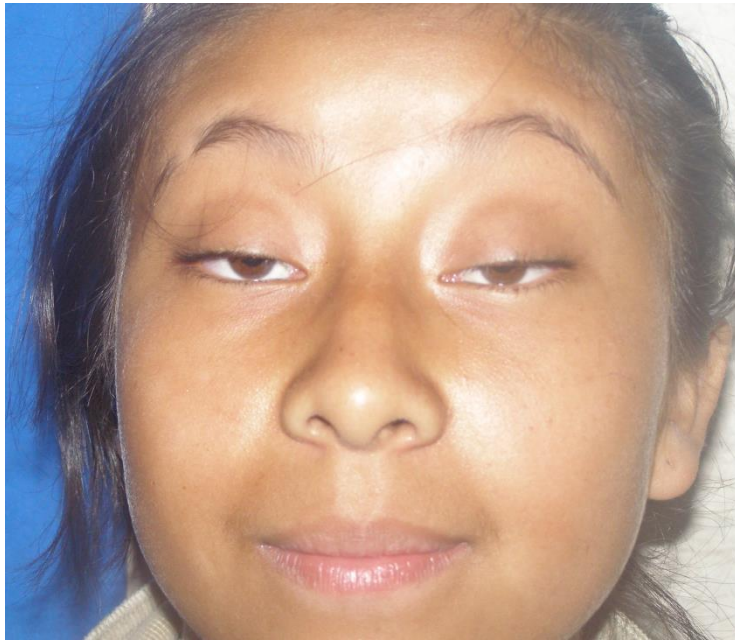




Complete ptosis, levator dehiscence.  
Patient would tape his eyelid to the rim of this hat to see.  
Frontalis Sling surgery

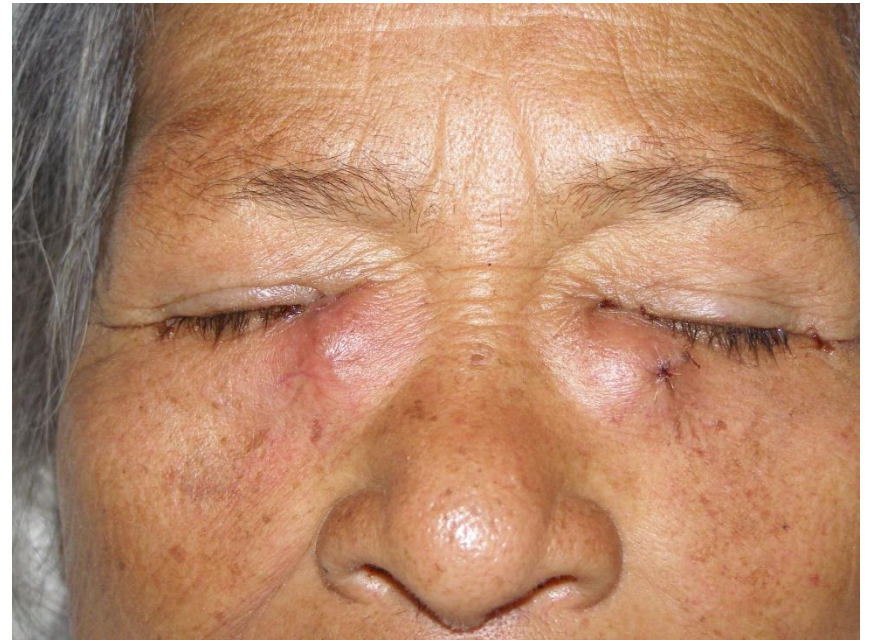
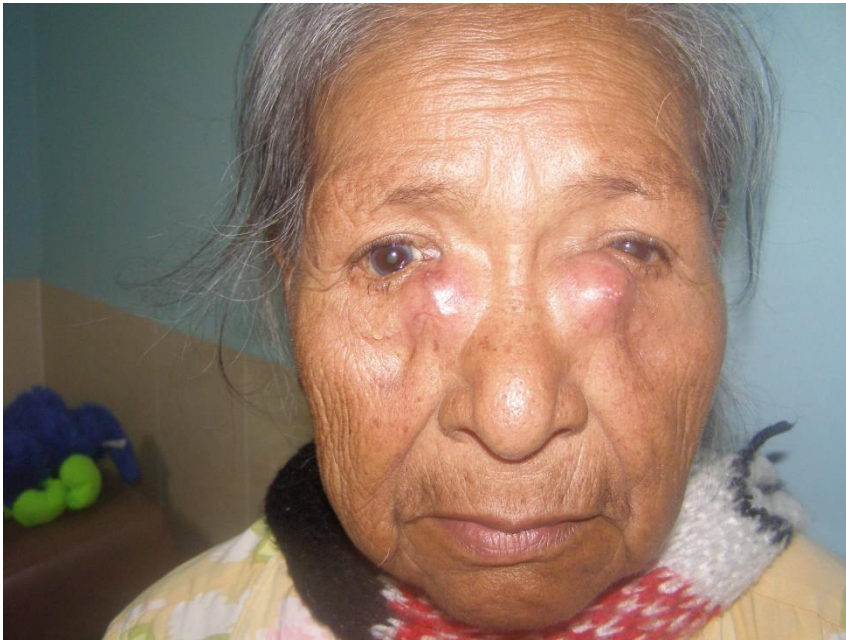

# Frontalis Sling

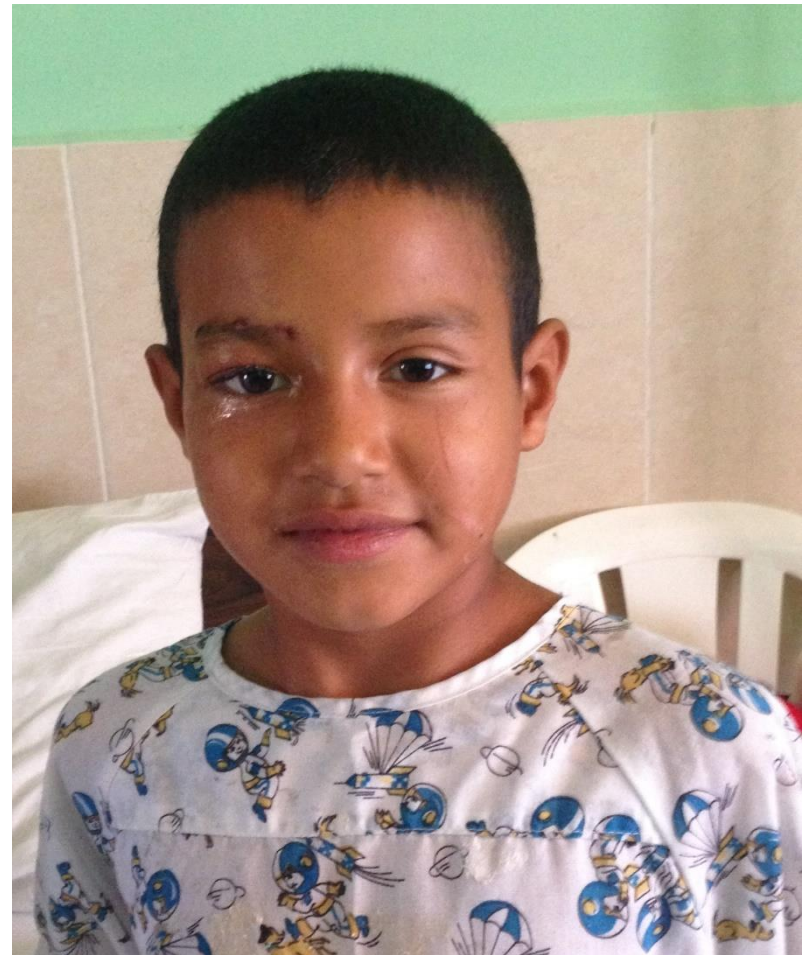
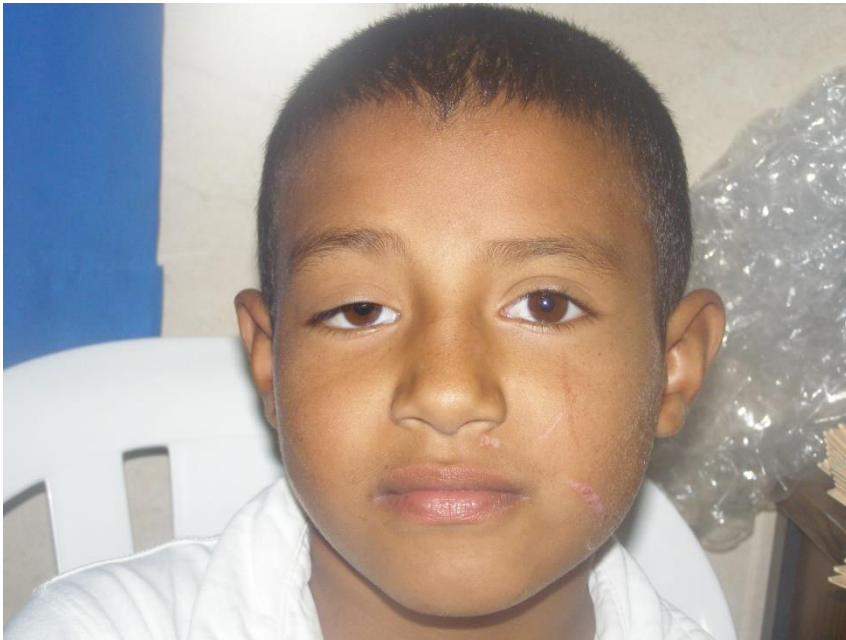


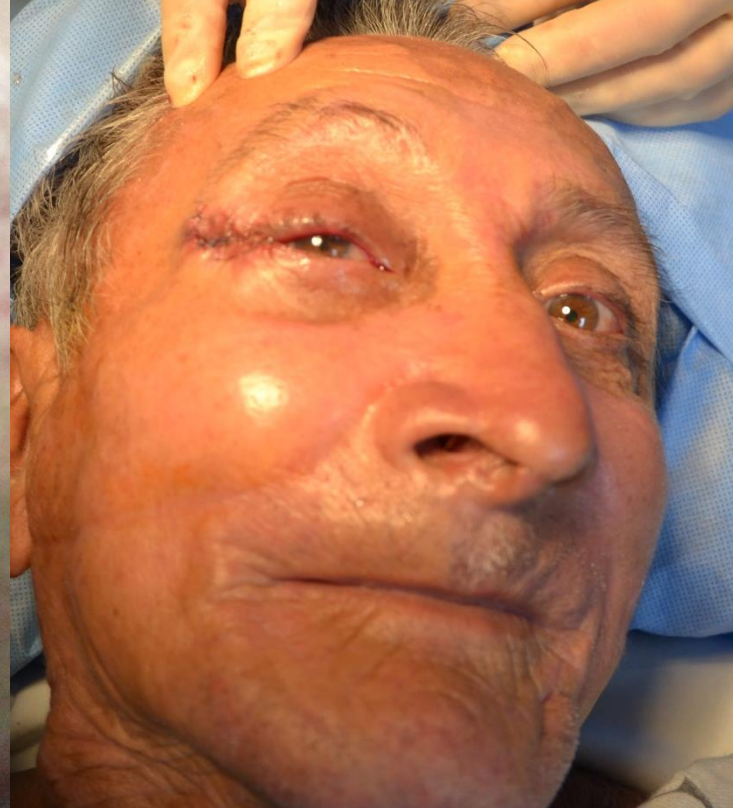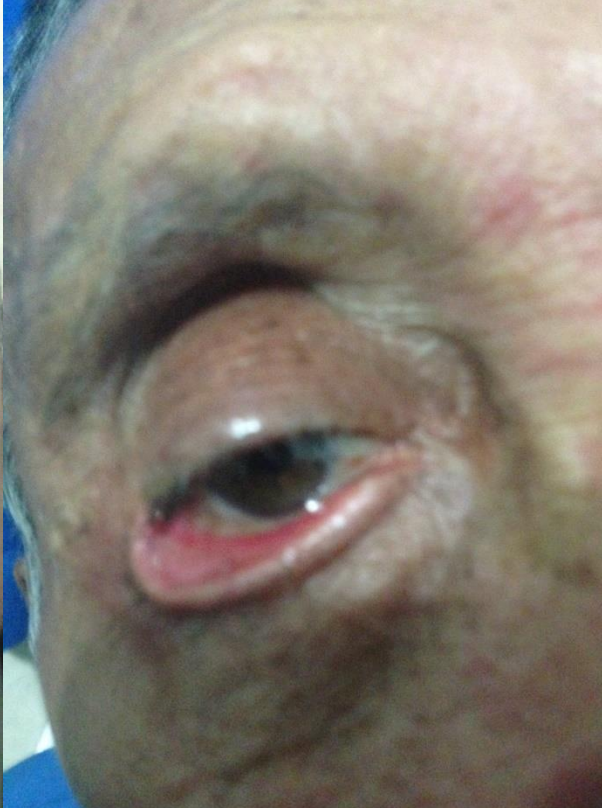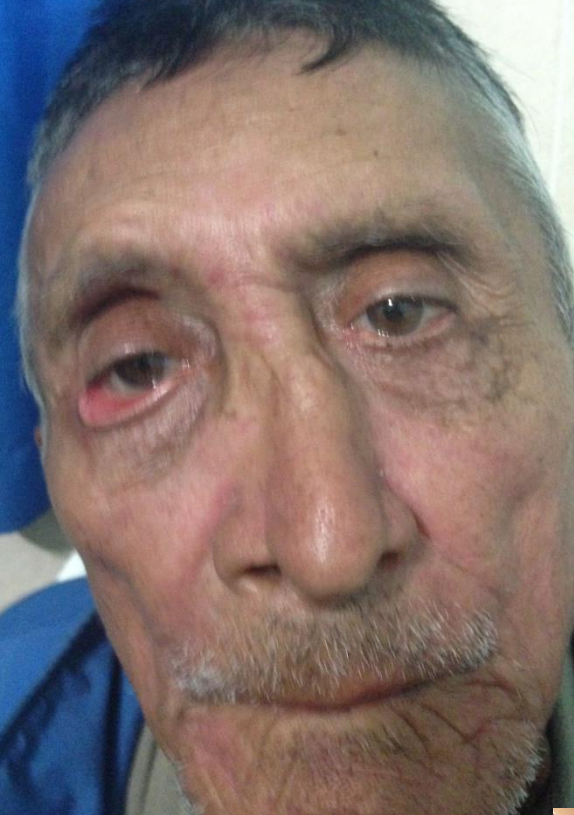# Painful Dacryocystitis X 2 yrs



# Frontalis Sling







Cicatricial ectropion repair.

9 months s/p 2 X4 wood plank fell on his face. The lower lid scar, contracted preventing him from being able to close his eyes













